

REVIEW ARTICLE—FOCUS ISSUE: MBF MEASUREMENT CT AND MRI

Quantitative Evaluation of Myocardial Ischemia with Dynamic Perfusion CT

Noriko Oyama-Manabe, MD, PhD¹⁾, Osamu Manabe, MD, PhD²⁾, Masanao Naya, MD, PhD³⁾, Kohsuke Kudo, MD, PhD¹⁾ and Nagara Tamaki, MD, PhD⁴⁾

Received: September 29, 2018/Revised manuscript received: October 16, 2018/Accepted: October 17, 2018

J-STAGE advance published: May 10 2019

© The Japanese Society of Nuclear Cardiology 2019

Abstract

Cardiac computed tomography (CT) could provide the comprehensive morphologic and functional information of coronary artery disease. Coronary CT angiography has been well established for identification and management of symptomatic patients with or suspected coronary artery disease. However, we should know the anatomical stenosis is not the same as the functional one needed to be treated. Dynamic perfusion imaging could lead a non-invasive quantitative evaluation of myocardial ischemia with estimation of myocardial blood flow. In this review, we address the characteristics and advantages of cardiac CT, in particular dynamic perfusion CT for quantitative evaluation of myocardial ischemia.

Keywords: Cardiac CT, Coronary artery disease, CT perfusion, Dynamic, Myocardial blood flow

Ann Nucl Cardiol 2019; 5 (1): 79–83

Cardiac computed tomography (CT) provides the comprehensive morphologic and functional information of coronary artery disease (CAD). Coronary CT angiography (CCTA) has been well established for identification and management of symptomatic patients with or suspected CAD. Additional pharmacological stress myocardial CT perfusion (CTP) imaging can detect ischemia in patients with CAD (1). Dynamic perfusion imaging could lead a non-invasive quantitative detection of myocardial ischemia with estimation of myocardial blood flow (MBF) same as positron emission tomography (PET). Nowadays, CT fractional flow reserve (CT_{FFR}) from CCTA has become available, which could also detect functional stenosis without stress test (2).

In this review, we address the characteristics and advantages of cardiac CT, in particular the dynamic CTP for quantitative evaluation of myocardial ischemia.

Morphological vs. functional assessment

CCTA has the advantage for coronary visualization with higher temporal and spatial resolution comparing to single positron emission tomography (SPECT)/ positron emission

tomography (PET) and magnetic resonance imaging (MRI). The diagnostic ability for detection of anatomically significant stenosis has been demonstrated in patients with both acute and stable CAD with very high negative predictive values (3–5). Therefore, CCTA has been accepted as a primary or secondary diagnostic option for the identification in symptomatic CAD patients with an intermediate likelihood (6). However, we should know the anatomical stenosis is not the same as the functional one to be treated by the percutaneous coronary intervention (PCI). The COURAGE (Clinical Outcomes Utilizing Revascularization and Aggressive Drug Evaluation) trial indicated that PCI based the anatomic estimation of coronary stenosis did not reduce the risk of death, myocardial infarction, or other major cardiovascular events of the stable CAD patients (7). In contrast, the qualitative and quantitative images from PET and SPECT are used for evaluating functional severity of CAD, which is influenced by both epicardial stenosis and microvascular disease (8). PET derived myocardial flow reserve (MFR), which is calculated by MBF at stress / MBF at rest, has been proposed as a functional parameter of the myocardial ischemia and to provide the

doi: 10.17996/anc.19-00087

1) Department of Diagnostic and Interventional Radiology, Hokkaido University Hospital, Sapporo, Japan

2) Department of Nuclear Medicine, Hokkaido University Graduate School of Medicine, Sapporo, Japan

3) Department of Cardiovascular Medicine, Hokkaido University Graduate School of Medicine, Sapporo, Japan

4) Department of Radiology, Kyoto Prefectural University of Medicine, Kyoto, Japan

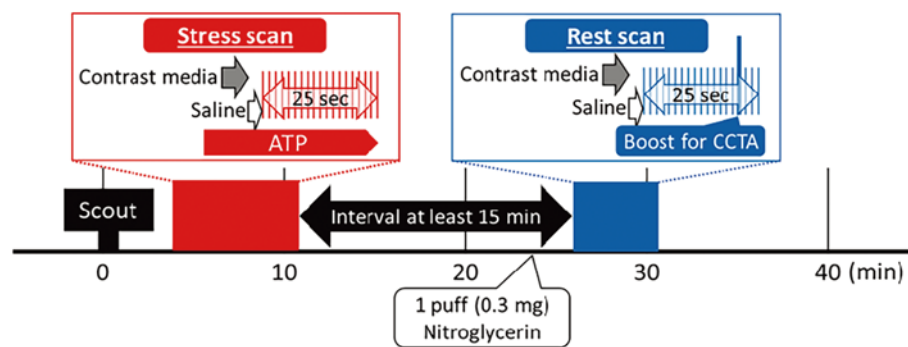


Figure 1 Protocol of dynamic stress and rest CT perfusion scan.

First, the stress scan was performed during the intravenous infusion of ATP (0.016 mg/kg/min) with prospective ECG triggering. Second, the rest dynamic CTP/ CCTA imaging was performed at least 15 min after the stress dynamic CTP.

incremental risk stratification for cardiac events (9, 10). Quantitative MBF derived from CTP in ischemic heart disease encompasses the functional evaluation of CAD. We reported hyperemic MBF evaluated by CTP had sufficient sensitivity, positive predictive value, and negative predictive value to detect obstructive CAD assessed by invasive coronary angiography in both per-patient and per-vessel analyses (11). Meta-analysis was recently published to determine the diagnostic utility of 6 cardiac functional imaging modalities such as CT_{FFR}, cardiac MRI, PET, CTP, SPECT and dobutamine stress echocardiography using FFR as the reference standard (12). In a per-patient and a per-vessel analysis, cardiac MRI, PET, CTP and CT_{FFR} expressed a similar high accuracy in detecting functional stenosis compared to SPECT. The advantage of CTP combined with CCTA is a comprehensive diagnostic tool for cardiac ischemia with accurate anatomic assessment in one examination (13).

Static vs. dynamic CT perfusion

CTP acquisitions are broadly separated into two categories as dynamic and static scan protocols. The first pass of iodine contrast media can be used for the hemodynamics to the myocardium. Static single-phase CTP imaging is highly dependent on the contrast material bolus timing. A drawback of static CTP is that the peak attenuation may be missed because only one sample of data is acquired (14). It is difficult to determine whether the static CTP image has been obtained at the optimal scan time that allows for a clear distinction between normal and ischemic myocardium. This is because the optimal scan time varies according to several factors, such as the severity of the coronary lesion and cardiac function. Previous studies reported that the optimal scan time for static single-phase CTP was 2–10s from the time of maximal enhancement in the ascending aorta (15, 16). Evaluation of the ischemic lesion is sometimes difficult only with qualitative evaluation from static scan due to the lower contrast resolution

of CT compare to that of CMR. On the other hand, dynamic CTP scan has several advantages such as selection of the appropriate timing from the multiple images and the time density curve to quantify the MBF. Higher exposure dose compared to the static scan and to require the latest multi-detector row CT devices are the disadvantages for the dynamic CTP scan.

Stress first vs. rest first protocol

When the stress imaging is performed first, the detection of myocardial ischemia is optimized because the myocardium is not contaminated by previous injection of contrast material, which may mask an area of ischemia (12). In addition, the administration of beta-blockers and nitrates before the rest image acquisition is allowed without interfering with stress perfusion assessment. On the other hand, rest CCTA first acquisition protocol, followed by a stress acquisition, is more suitable for patients with a low-to intermediate pretest probability of CAD, which allows discontinuation of the protocol when absent or minimal CAD is detected (17).

Quantification of MBF and MFR

The detailed method of dynamic perfusion CT in our institute has been previously reported (11). Dynamic CTP protocol used in our institution is shown in Figure 1. A non-contrast image is obtained to determine the Agatston score. Then, during a continuous 6-min infusion of adenosine triphosphate (ATP), hyperemic dynamic CTP scan is performed for 25 sec with 50 mL of iodinated contrast (350 mg I/mL) and 30 mL saline chaser (5.0 mL/sec). Resting CTP with a boost scan for CCTA is performed after approximately 15-min interval after the ATP infusion. An intravenous administration of propranolol (up to 10 mg) is used when the heart rate for CCTA is greater than 65 beats per minutes. Both stress and rest images are scanned under the continuous electrocardiogram (ECG) monitoring for prospective trigger-

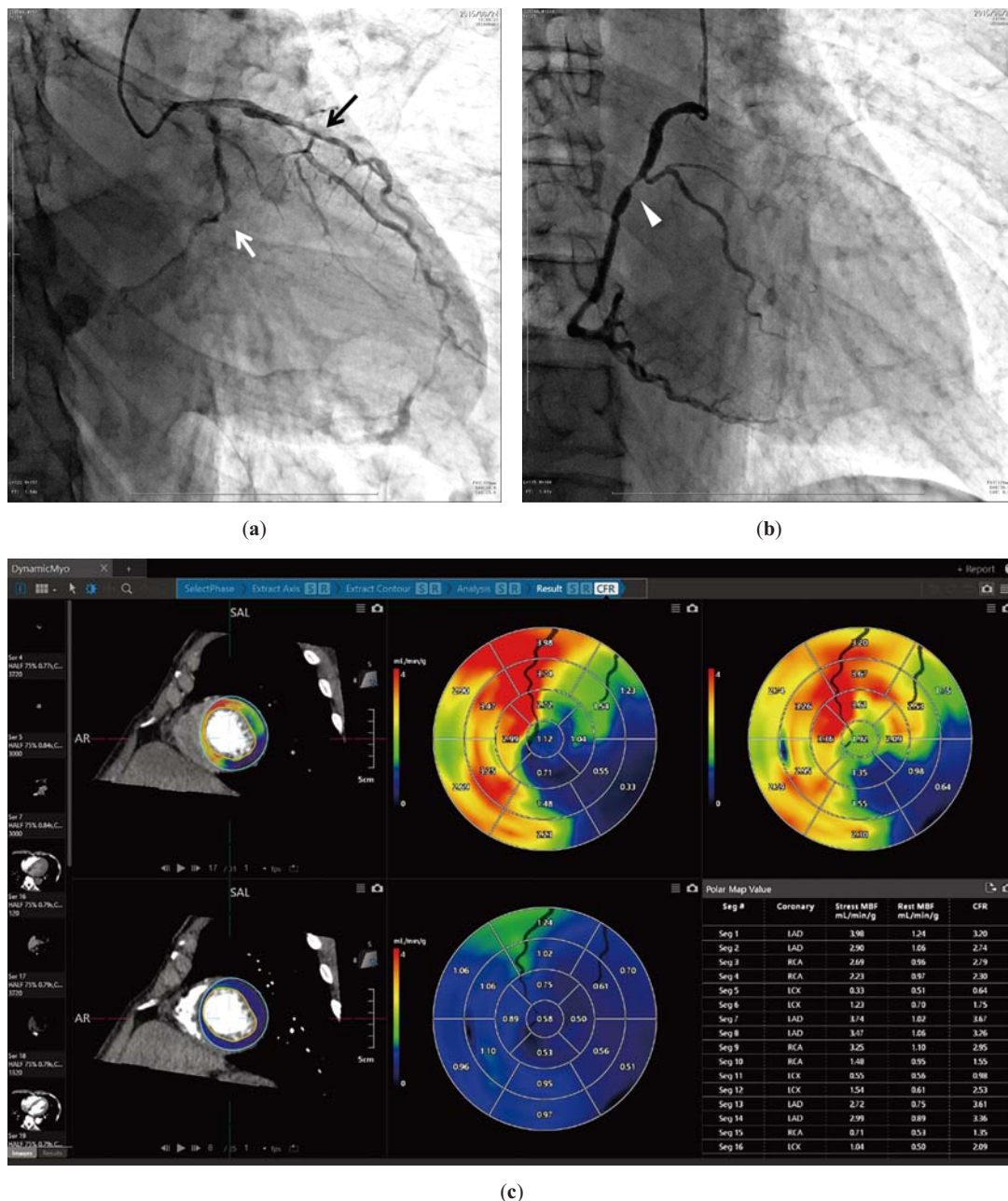


Figure 2 Representative case of coronary artery disease.

Asymptomatic 70s male with hypertension underwent cardiac CT for screening before abdominal aortic aneurysm operation.

Invasive coronary angiography (ICA) (left; **a** and right; **b**):

ICA showed 3-vessel disease in the LAD (black arrow, **a**), RCA (arrowhead, **b**) and LCX. LCX showed chronic total occlusion (white arrow) (**a**).

CTP analysis (**c**):

CTP images represented severe ischemia (blue color) in the LCX territory and moderate to severe ischemia (orange-yellow color) in the RCA and LAD territories.

LAD: left anterior descending artery, LCX: left circumflex artery, RCA: right coronary artery

ing. Patients are advised to avoid caffeine (coffee, tea, chocolate, energy drinks, etc) for 24 hours before undergoing stress imaging because it may affect the vasodilator capacity of adenosine during stress (14).

For evaluation of MBF, time attenuation curves are generated from the region of interests of the myocardium and the LV blood cavity. We have developed the algorithm for

calculation of MBF using a single-tissue compartment model with the Renkin-Crone equation validated by ^{15}O -water PET (13). MFR is calculated as the ratios of hyperemic MBF to resting MBF. Our algorithm is now commercially available (Myocardial Dynamic Perfusion software, Vitrea workstations, Vital images Inc. USA) with Aquilion ONE ViSION edition (Canon Medical systems, Japan) (Figure 2). Per-

patient and per-vessel hyperemic MBF and MFR derived dynamic CTP had moderate diagnostic values for detecting obstructive CAD (11). Those parameters can be used to identify the functionally obstructive coronary lesions (18).

Radiation dose reduction

Recently, reconstruction methods have been making remarkable progress which reduce the image noise. Iterative reconstruction (IR) method has been used instead of traditional filtered back projection (19). IR method allows the scan with a lower voltage (80 kV) which leads to the improvement of image contrast and reduction of the amount of contrast medium. We used prospective scan at low tube voltage (80 kV) with the hybrid IR for radiation and noise reduction, and validated the MBF with ^{15}O -water PET, known as a gold standard for quantification of MBF (11, 15). In these ways, stress and rest myocardial CTP can be done with the lower radiation exposure compared to the combination of traditional SPECT and CCTA scans at 120 kV.

Conclusion

Stress dynamic CTP with CCTA protocol using 80 kV allow comprehensive anatomical and functional assessments regarding quantitative MBF.

Acknowledgments

None.

Sources of funding

None.

Conflicts of interest

N.O.M., M. N. and T. N. Activities related to the present article: consultant for Canon Medical Systems.

N.O.M. Activities not related to the present article: grants or grants pending from Japan Society for the Promotion of Science (JSPS) KAKENHI; payment for lectures from Daiichi-Sankyo Co. Ltd, Philips Medical Systems, Eisai Co. Ltd, Bayer Healthcare, and Canon Medical Systems.

K.K. Activities related to the present article: disclosed no relevant relationships. Activities not related to the present article: grants or grants pending from AMED, JSPS KAKENHI, Hitachi Medical Systems, and Bayer Healthcare; payment for lectures from Hitachi Medical Systems, Daiichi-Sankyo Co. Ltd, Bayer Healthcare, GE Healthcare, Philips Medical Systems, Siemens Healthineers, and Canon Medical Systems.

Reprint requests and correspondence:

Noriko Oyama-Manabe, MD, PhD

Department of Diagnostic and Interventional Radiology,
Hokkaido University Hospital, N15 W4, Kita-Ku, Sapporo,
060-8638 Hokkaido, Japan

E-mail: norikooyama@med.hokudai.ac.jp

References

1. Ramsey BC, Fentanes E, Choi AD, et al. Myocardial assessment with cardiac CT: Ischemic heart disease and beyond. *Curr Cardiovasc Imaging Rep* 2018; 11: 16.
2. Min JK, Taylor CA, Achenbach S, et al. Noninvasive fractional flow reserve derived from coronary CT angiography: Clinical data and scientific principles. *JACC Cardiovasc Imaging* 2015; 8: 1209–22.
3. Miller JM, Rochitte CE, Dewey M, et al. Diagnostic performance of coronary angiography by 64-row CT. *N Engl J Med* 2008; 359: 2324–36.
4. Meijboom WB, Meijs MF, Schuijf JD, et al. Diagnostic accuracy of 64-slice computed tomography coronary angiography: a prospective, multicenter, multivendor study. *J Am Coll Cardiol* 2008; 52: 2135–44.
5. Budoff MJ, Dowe D, Jollis JG, et al. Diagnostic performance of 64-multidetector row coronary computed tomographic angiography for evaluation of coronary artery stenosis in individuals without known coronary artery disease: results from the prospective multicenter ACCURACY (Assessment by Coronary Computed Tomographic Angiography of Individuals Undergoing Invasive Coronary Angiography) trial. *J Am Coll Cardiol* 2008; 52: 1724–32.
6. Fihn SD, Gardin JM, Abrams J, et al. 2012 ACCF/AHA/ACP/AATS/PCNA/SCAI/STS Guideline for the diagnosis and management of patients with stable ischemic heart disease: a report of the American College of Cardiology Foundation/American Heart Association Task Force on Practice Guidelines, and the American College of Physicians, American Association for Thoracic Surgery, Preventive Cardiovascular Nurses Association, Society for Cardiovascular Angiography and Interventions, and Society of Thoracic Surgeons. *J Am Coll Cardiol*. 2012; 60: e44–e164.
7. Boden WE, O'Rourke RA, Teo KK, et al. Optimal medical therapy with or without PCI for stable coronary disease. *N Engl J Med* 2007; 356: 1503–16.
8. Manabe O, Naya M, Tamaki N. Feasibility of PET for the management of coronary artery disease: Comparison between CFR and FFR. *J Cardiol* 2017; 70: 135–40.
9. Murthy VL, Naya M, Foster CR, et al. Improved cardiac risk assessment with noninvasive measures of coronary flow reserve. *Circulation* 2011; 124: 2215–24.
10. Taqueti VR, Hachamovitch R, Murthy VL, et al. Global coronary flow reserve is associated with adverse cardiovascular events independently of luminal angiographic severity and modifies the effect of early revascularization. *Circulation* 2015; 131: 19–27.
11. Obara M, Naya M, Oyama-Manabe N, et al. Diagnostic value

- of quantitative coronary flow reserve and myocardial blood flow estimated by dynamic 320 MDCT scanning in patients with obstructive coronary artery disease. *Medicine (Baltimore)* 2018; 97: e11354.
12. Dai N, Zhang X, Zhang Y, et al. Enhanced diagnostic utility achieved by myocardial blood analysis: A meta-analysis of noninvasive cardiac imaging in the detection of functional coronary artery disease. *Int J Cardiol* 2016; 221: 665–73.
 13. Kikuchi Y, Oyama-Manabe N, Naya M, et al. Quantification of myocardial blood flow using dynamic 320-row multidetector CT as compared with 15O-H₂O PET. *Eur Radiol* 2014; 24: 1547–56.
 14. Rossi A, Merkus D, Klotz E, et al. Stress myocardial perfusion: imaging with multidetector CT. *Radiology* 2014; 270: 25–46.
 15. Bischoff B, Bamberg F, Marcus R, et al. Optimal timing for first-pass stress CT myocardial perfusion imaging. *Int J Cardiovasc Imaging*. 2013; 29: 435–42.
 16. Tanabe Y, Kido T, Kurata A, et al. Optimal scan time for single-phase myocardial computed tomography perfusion to detect myocardial ischemia- derivation cohort from dynamic myocardial computed tomography perfusion. *Circ J* 2016; 80: 2506–12.
 17. Seitun S, Castiglione Morelli M, Budaj I, et al. Stress computed tomography myocardial perfusion imaging: a new topic in cardiology. *Rev Esp Cardiol (Engl Ed)* 2016; 69: 188–200.
 18. Rossi A, Dharampal A, Wragg A, et al. Diagnostic performance of hyperaemic myocardial blood flow index obtained by dynamic computed tomography: does it predict functionally significant coronary lesions? *Eur Heart J Cardiovasc Imaging* 2014; 15: 85–94.
 19. Fareed A, Vavere AL, Zimmermann E, et al. Impact of iterative reconstruction vs. filtered back projection on image quality in 320-slice CT coronary angiography: Insights from the CORE320 multicenter study. *Medicine (Baltimore)* 2017; 96: e8452.